



PATIENT

Stella Yengendorf

SPECIES

Canine

BREED

Yorkshire Terrier Mix

SEX

Female

AGE

13 years

WEIGHT

6.3kgs

INTERPRETED BY

Maggie Machen Lamy,
DVM, DACVIM
(Cardiology)

IMAGING PERFORMED BY

Nigel Gumley, DVM

HOSPITAL NAME

Cedarview Animal
Hospital

REFERRING VET

Dr. Gumley

INVOICE

21636

DATE

10/19/21

PRESENTING CLINICAL SIGNS

History: Previously seen by another vet for suspect congestive heart failure and placed on furosemide and Vetmedin. No cough or exercise intolerance. Owner stopped furosemide due to incontinence. Now clinically better but Pu/PD.

-Abnormal PE/Chem/CBC/UA Results: Urine sp gr = 1.012, normal BW No murmur audible today. Mass adjacent to R adrenal discovered on abdominal US, diagnosis pending.

ECHOCARDIOGRAM FINDINGS

2D, m-mode, color flow and doppler imaging is available. Mild diffuse thickening of mitral valve leaflets with no obvious prolapse into the left atrial lumen. No MR. No LA dilation. Increased LV wall thickness; symmetrical (0.92cm). Normal LV diameter with adequate myocardial function. The tricuspid valve appears normal with no tricuspid regurgitation. Normal right atrial and ventricular diameter and morphology indicating no overt evidence of pulmonary arterial hypertension. The pulmonic and aortic valves are normal in morphology and mobility. Normal pulmonic and aortic outflow velocities with laminar flow. No obvious aortic insufficiency. Trivial pulmonic insufficiency. No pericardial or pleural effusion noted. No obvious cardiac masses.

CARDIAC CHART

CANINE CARDIAC PARAMETERS	MR VMAX (m/s)	TR VMAX (m/s)	LA/AO (Boon method)	LA/AO (Heart Base; Swe)	FS (%)	EF (%)	EPSS (cm)
NORMAL PARAMETER	4.5-5.5	<2.7	1.3	<1.6	28-40	40-100	<0.6
PATIENT	NA	NA	1.4	1.2	66	94	NM
CANINE CARDIAC PARAMETERS	HR (BPM)	AV VMAX (m/s)	PV MAX (m/s)	BODY WEIGHT (kg)	LA 2D short axis Base view (cm)	LVIDd Avg; 2D and m-mode short axis (cm)	LVIDs Avg; 2D and m-mode short axis (cm)
NORMAL PARAMETER	50-100	0.7-1.7	0.7-1.6	BELOW	BELOW	BELOW	BELOW
PATIENT	NM	1.66	1.1	6.3	1.5	1.8	0.6
*Normal chamber parameters expressed as a mean value (SD)				3	1.27 (5.3)	2.46 (2.46)	1.36 (5.5)
BODY WEIGHT DEPENDENT PARAMETERS				5	1.40 (4.5)	2.74 (5.2)	1.60 (4.7)
<i>*Note: All measurements based upon multi-modal images and methods. An average value is reported.</i>				10	1.50 (3.8)	3.27 (3.5)	2.06 (3.1)
				15	1.83 (2.0)	3.71 (2.4)	2.43 (2.1)
				20	2.02 (1.9)	4.14 (2.2)	2.80 (2.0)
				25	2.18 (2.4)	4.48 (2.9)	3.10 (2.5)
				30	2.33 (3.3)	4.83 (3.9)	3.39 (3.4)
				35	2.48 (4.3)	5.17 (5.0)	3.69 (4.5)
				40	2.62 (5.2)	5.48 (6.1)	3.96 (5.4)
				50	2.88 (7.1)	6.07 (8.3)	4.46 (7.4)

Adapted from June Boon, Veterinary Echocardiography, 1998
Rishniw M and Hollis NE, J Vet Intern Med 2000; 14:429-435
Hansson et al, Vet Rad and Ultrasound 2002
Bonagura et al. Echocardiography: principles of interpretation, Vet Clin North Am 15:1177, 1995



PATIENT

Stella Yengendorf

SPECIES

Canine

BREED

Yorkshire Terrier Mix

SEX

Female

AGE

13 years

WEIGHT

6.3kgs

INTERPRETED BY

Maggie Machen Lamy,
DVM, DACVIM
(Cardiology)

**IMAGING
PERFORMED BY**

Nigel Gumley, DVM

HOSPITAL NAME

Cedarview Animal
Hospital

REFERRING VET

Dr. Gumley

INVOICE

21636

DATE

10/19/21

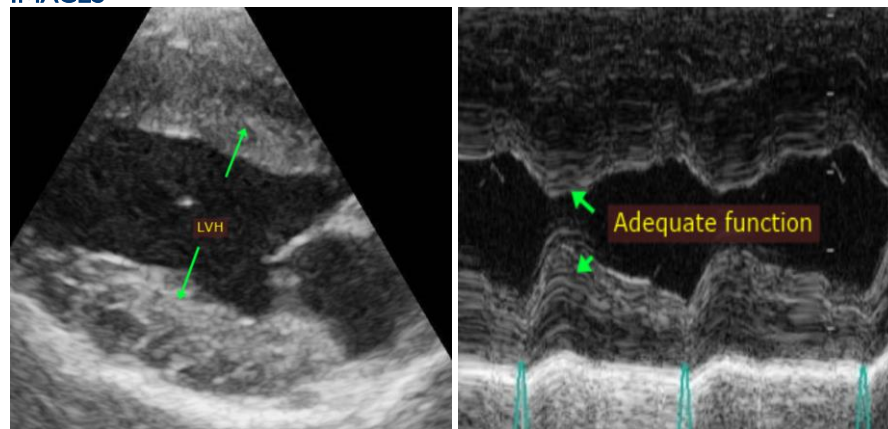
INTERPRETATION OF THE FINDINGS & FURTHER RECOMMENDATIONS

The primary abnormality noted on this exam is significant LV hypertrophy. The hypertrophy appears symmetrical, and rule outs for this finding in the absence of a stenosis include systemic hypertension, primary HCM (similar to a cat; rare in a dog), dehydration/hypovolemia or potentially an infiltrative process in the myocardium. A screening BP is highly recommended (preferably utilizing a Doppler given the small size of the dog), particularly in light of an adrenal tumor. No concurrent issues and the overall cardiac function is normal.

From a structural standpoint, no cardiac medications are clearly indicated and Lasix and Pimobendan should certainly not be utilized. The LA is mildly indicated indicating a low risk for congestive heart failure or predictable complications. Monitor for development of any associated clinical signs or development of a heart murmur. A cough in this patient would be due to respiratory disease rather than CHF. Baseline chest radiographs are recommended should this symptom develop.

If BP is persistently elevated >150mmHg, vasodilation using amlodipine is recommended. If patient is deemed normotensive, a full systemic work up to screen for/rule out potential infiltrative diseases such as neoplasia is recommended. If no abnormalities are identified, a primary HCM is suspected and a recheck of LA/LV dimensions is recommended in 6 months.

IMAGES



The information and recommendations provided are based on the images presented by the referring veterinarian. No evaluation can be communicated regarding pathology that was not visible in the image/video clips provided.

Thank you for this referral. This report was generated using transcription software, and minor dictation errors may be present. If the clinical or image interpretation does not parallel your findings or if I can be of any further assistance, please contact me.

Maggie Machen Lamy, DVM
Diplomate of the American College of Veterinary Internal Medicine (Cardiology)
info@sonopath.com